

Angio-Seal[®]

Vascular Closure Device

GOOD ACCESS GOOD CLOSURE

REFERENCE GUIDE

George V. Moukarbel, M.D. and Frederic S. Resnic, M.D., M.S.c.



 **TERUMO**
INTERVENTIONAL
SYSTEMS

TABLE OF CONTENTS

Introduction	4-5
A Suggested Approach to Femoral Vascular Puncture	6-12
Femoral Access	
Femoral Artery and Related Vessels: Relationship to Adjacent Structures	
Locating the needle's entry site: which landmarks to use?	
Femoral Angiography	
Complications of Femoral Access	
ANGIO-SEAL Device: Angiographic Selection Criteria	
Summary	13
Patient Case Studies	15-24
References	25-26


INTRODUCTION

An interventionalist's access technique is a critical success factor in preventing vascular access complications. Strict attention to anatomic landmarks maximizes the likelihood of successful access and minimizes complications.¹ Fluoroscopic imaging to identify the mid-line of the femoral head is useful in guiding appropriate femoral access and is recommended as a routine step for all femoral access procedures performed in the catheterization laboratory.

Vascular closure devices continue to gain acceptance from interventional cardiology and vascular radiology specialists to provide rapid hemostasis, faster ambulation and improved patient comfort compared to manual compression.² In addition to these benefits, sizable studies show that vascular closure can help reduce complications.³⁻⁶ Marso recently described a study that included more than 1.5 million patients, showing a 23% reduction in bleeding events when vascular closure was used compared to manual compression.³

Angiography of the femoral vessels through the sheath and before the start of coronary angiography or intervention is also highly recommended as a best practice protocol to identify the sheath location relative to the inferior epigastric artery (IEA) and the femoral artery bifurcation.

ANGIO-SEAL® VIP



A SUGGESTED APPROACH TO FEMORAL VASCULAR PUNCTURE

Femoral access

Recently published data from the National Cardiovascular Data Registry (NCDR) shows that femoral access is by far the most prevalent access site for cardiac catheterization and interventions⁷ performed in the United States. The preference for femoral access is multifactorial and includes ease of catheter maneuverability and versatility of femoral access compared to other access sites,⁸ as well as the excellent backup support achievable via the femoral access approach. Knowledge of the femoral vascular anatomy and its relationship to nearby structures and landmarks can help guide appropriate localization of the arterial puncture site. Optimizing the femoral access technique is an ideal strategy for minimizing the risks associated with vascular access for cardiac catheterization and intervention.

The goal of optimum femoral access for cardiac catheterization procedures is to secure a minimally traumatic arteriotomy entry point in the common femoral artery, in a region overlying the femoral head, for the following reasons:

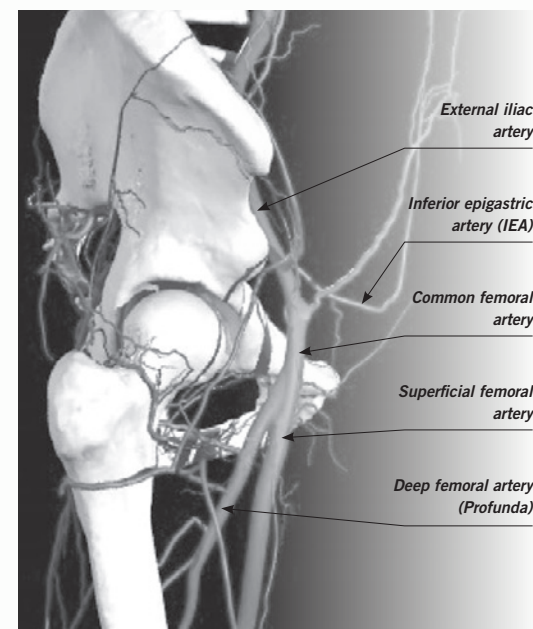
1. Manual compression of the artery after sheath removal is more effective against the femoral head than against soft tissues.
2. Lower entry points increase the risk of entry at or below the bifurcation of the common femoral artery, which places the sheath in the superficial or profunda femoral artery. This predisposes development of several complications:
 - a. pseudoaneurysm formation because of the inability to compress the artery wall against the surrounding soft tissues¹
 - b. arteriovenous fistula formation because of close proximity/overlap of the vein and artery below the bifurcation¹
3. High access site location increases the risk of developing retroperitoneal bleeding,^{9,10} a potentially lethal vascular complication, because of the inability to achieve adequate hemostasis by either manual compression or vascular closure devices.

Femoral artery and related vessels: relationship to adjacent structures

The external iliac artery courses underneath the inguinal ligament, and becomes the common femoral artery. The femoral artery then bifurcates to form the superficial femoral artery and the profunda femoral artery. The inferior epigastric artery branches off the external iliac artery before it traverses the inguinal ligament. The inferior epigastric artery initially courses downward and then reflects upward around the inguinal ligament, forming a U-shaped trajectory.

The most inferior border of the inferior epigastric artery marks the inferior border of the retroperitoneal space.¹¹ Therefore, an access site above this landmark is most likely above the inguinal ligament and is associated with a high risk of retroperitoneal bleeding.

However, bleeding can still occur with an access site below the inguinal ligament if the femoral sheath, which wraps around the femoral artery and is in communication with the retroperitoneal space, is traversed by the access catheter.¹²



Adapted from Primal Pictures Ltd. ©2000.

A SUGGESTED APPROACH TO FEMORAL VASCULAR PUNCTURE

Locating the needle's entry site: which landmarks to use?

Anatomical landmarks: are they reliable?

The usual external anatomical landmarks used to guide femoral access are the inguinal crease, the point of maximal impulse and a line between the anterior-superior iliac crest and the pubic tubercle to locate the inguinal ligament.¹¹ These landmarks are notoriously unreliable as their relationship to the underlying vascular anatomy can vary widely among patients. For example, the inguinal crease can be significantly displaced inferiorly, especially in overweight/obese patients. An inguinal crease-guided puncture is commonly located below the common femoral artery bifurcation.¹³ The inguinal ligament commonly overlies the upper half of the femoral head; therefore, a puncture below this line can sometimes lead to a low access site. Finally, the point of maximal impulse does not necessarily represent the most superficial location of the vessel or the location anterior to the femoral head. It can also be difficult to determine, especially in the presence of atherosclerotic vascular disease, which often presents significant calcifications.

Fluoroscopic guidance

Use of fluoroscopy to delineate the femoral head anatomy is very useful in guiding appropriate femoral access and is recommended as a routine step for all catheterization laboratory-based femoral access procedures.

Since the inferior epigastric artery rarely courses below the center of the femoral head,¹¹ and the femoral artery bifurcates at or below the bottom of the femoral head in about three-quarters of patients,^{13,14} an optimal location of the needle entry site would be just below the midline of the femoral head (Figure 1). This entry location is highly likely to be (a) below the inferior border of the inferior epigastric artery, and (b) above the common femoral bifurcation.

A hemostat is used to determine the location of the borders of the lower half of the femoral head by fluoroscopy (Figure 2 – A & B), and the skin is entered a few millimeters below the desired arterial entry site to allow an appropriately 45° angulation of the entry needle into the vessel. Once the needle is at the level of the arterial wall, and before the actual vessel puncture, arterial pulsations can be felt by the operator through the access needle. Fluoroscopy can confirm the presence of the needle tip at the desired location relative to the midpoint of the femoral head before proceeding with entry into the vessel lumen (Figure 3). Additional confirmation can be obtained after introducing the guidewire through the needle; slight displacement of the needle sideways under live fluoroscopy can reveal the position of the tip of the needle relative to the femoral head.

Figure 1. Aorto-iliac angiogram showing the relationship of the femoral vessels to neighboring structures. The straight dashed line represents a line drawn from the anterior superior iliac spine to the pubic symphysis. The location of the optimal puncture site relative to the femoral head is indicated.

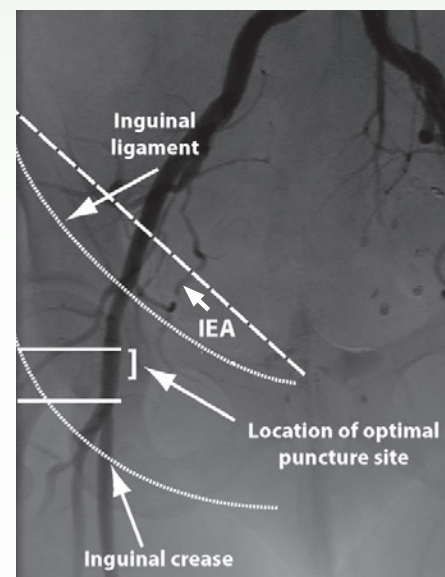


Figure 2. Use of the hemostat to identify the location of the inferior border (panel A) and the center (panel B) of the femoral head prior to skin puncture.

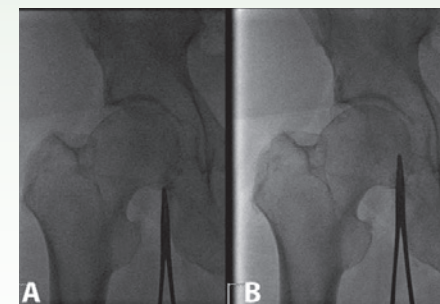
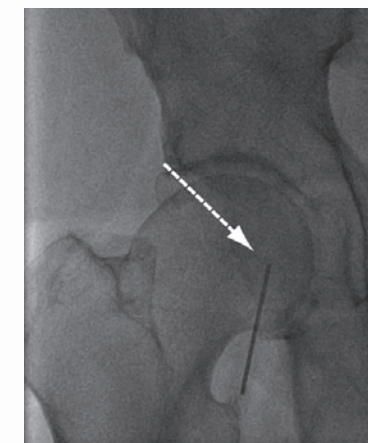


Figure 3. Appropriate location of the needle tip (arrow) is confirmed under fluoroscopy before arterial puncture.



Ultrasound guidance

Ultrasound can also be used to optimize femoral access. The artery can be visualized in cross section, with the transducer swept superiorly and inferiorly to identify the location of the femoral bifurcation. Color Doppler can be used to differentiate the artery from a vein. Also, vessel wall pulsations can usually be visualized on B-mode imaging. Direct visualization of the needle entering the vessel lumen can be performed relatively easily, which can minimize the number of needle passes and venous entry.¹⁵ This can be especially helpful with obese patients and in those with diminished pulses due to peripheral arterial disease.¹⁶ Unfortunately, ultrasound guidance is not very helpful in avoiding high puncture site locations, as it is difficult to identify the location of the inguinal ligament. Therefore, ultrasound should be considered complementary to use of fluoroscopic landmarks as described above.

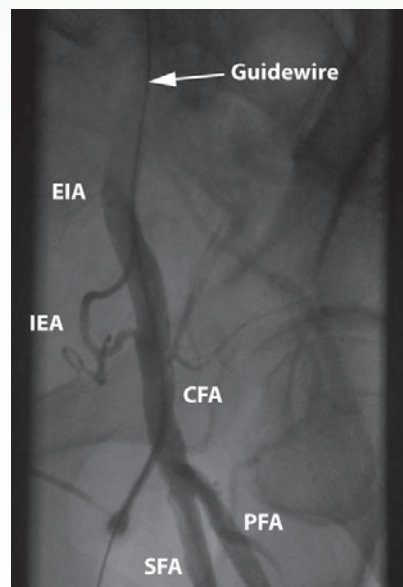
A SUGGESTED APPROACH TO FEMORAL VASCULAR PUNCTURE

Femoral angiography

After inserting the access sheath over the guidewire and before starting coronary angiography or intervention, angiography of the femoral vessels through the sheath is highly recommended in order to:

1. Precisely identify the location of the entry of the sheath relative to the IEA and the femoral artery bifurcation.
2. Identify potential bleeding sites around the entry point, seen as extravasation of radiographic contrast.
3. Assess the size of the vessel relative to the access sheath, and ensure that the sheath is non-occlusive in the vessel. This is especially important in female patients and any patient with diabetes, or low body surface area¹⁴ who typically have smaller sized vessels.
4. Assess the presence and extent of local ilio-femoral peripheral vascular disease.
5. Provide the anatomy of the femoral vessels and their relationship to the femoral head, thereby assisting in future access on the same patient.

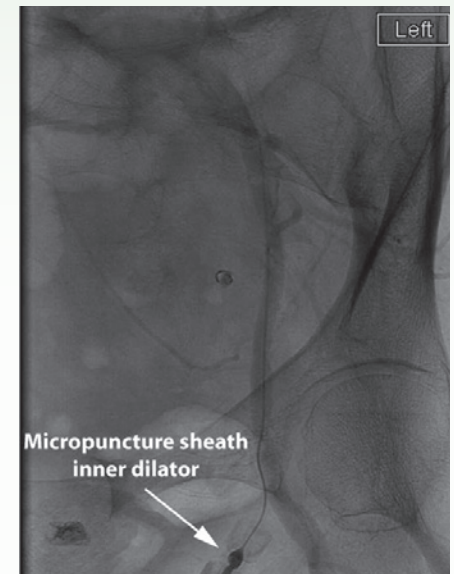
Figure 4. Femoral angiogram obtained after placement of the access sheath with medial tension applied to the sheath to show the entry site. The guidewire was left in the distal descending aorta as a safety measure in case the sheath gets pulled out of the artery during the angiogram.



This information can help assess the risk of bleeding with anticoagulation if an intervention is contemplated¹⁶ and plan access site management at the end of the procedure (manual compression vs. deployment of a closure device). The femoral angiogram is usually performed by injection of radiographic contrast through the side-arm of the access sheath. Typically, about 5-7 cc of diluted contrast material provides adequate opacification of the vessels. A cine loop or a stored fluoroscopic sequence is captured with ipsilateral oblique angulation (20-40°) in order to avoid the overlap of the superficial and profunda femoral arteries. In some cases, a contra-lateral view can be also helpful. Slight medial tension applied to the side-arm of the sheath will make the entry point of the sheath more evident. Care should be taken to avoid excessive tension on the side-arm as this can lead to the sheath being dislodged from the artery. Some operators prefer to leave the guidewire in the distal aorta during this step as a safety measure (Figure 4).

Many experienced operators recommend using a micropuncture (21-gauge) access needle routinely when accessing the femoral artery. Using a micropuncture needle, the operator can place the inner dilator (~1 mm in diameter) of the micropuncture sheath over the wire, and perform a femoral angiogram through the inner dilator to confirm adequate position of the entry site (Figure 5). If the entry site is deemed unfavorable (too high or too low), one can remove the micropuncture dilator, apply manual pressure to achieve hemostasis, and then re-access the femoral artery at an optimal location based on the angiogram. This method avoids placing a large bore sheath in an unfavorable location, and is especially helpful in patients with advanced vascular disease, hostile groin, or who are undergoing percutaneous valve interventions or placement of cardiac assist devices.

Figure 5. Left femoral angiogram obtained through the micropuncture sheath inner dilator to confirm optimal access site location, prior to placement of a larger bore sheath.



Complications of femoral access

Several complications of femoral access have been recognized. The incidence of each varies according to published series, and definitions. The most common complication is bleeding at the access site – usually superficial and controllable by manual compression. Retroperitoneal bleeding is much less common, however carries a high rate of morbidity and mortality.^{10,17} It requires prompt recognition and supportive management, and sometimes catheter-based or surgical intervention to prevent massive blood loss. Pseudoaneurysms, which represent contained perforations of the vessels, have been recognized with the more frequent use of vascular ultrasound for diagnosis.

Small, (< 2-3 cm) asymptomatic pseudoaneurysms tend to resolve spontaneously and can be managed conservatively, whereas larger ones that are associated with symptoms or evidence of compression of nearby structures are at risk of spontaneous rupture and should be treated by ultrasound-guided compression, thrombin injection or surgical excision.^{1,18-20} Other rare complications include infection, nerve damage, flow-limiting arterial dissection and arteriovenous fistulae.

A SUGGESTED APPROACH TO FEMORAL VASCULAR PUNCTURE

ANGIO-SEAL device: angiographic selection criteria²¹

In considering patients for the ANGIO-SEAL device, reviewing the femoral angiogram should include a careful assessment of the following parameters:

Puncture location – The vessel puncture should be located in the common femoral artery, proximal to the bifurcation of the superficial femoral and profunda femoral artery. Do not use the ANGIO-SEAL device if the puncture site is proximal to the inguinal ligament, as this may result in a retroperitoneal hematoma. In addition, there should be no large branch vessels at or 2 cm proximal to the access site into the vessel.

Vessel size – The target vessel should be 4 mm or greater in diameter. Smaller diameter vessels should not be considered for puncture closure with the ANGIO-SEAL device because of the increased potential for vascular complications.

The outside diameter of the procedure sheath can be used as a reference to estimate the vessel's inner diameter.

Remember to convert the inner diameter of the sheath to millimeters by dividing the sheath's French size by three. For example, 8 Fr procedure sheaths have an inner diameter of almost 2.7 mm. Accordingly, a vessel that appears to be two times the diameter of the inner lumen of an 8 Fr procedure sheath would be estimated to be about 5.4 mm in diameter.

Deterrents – The femoral angiogram also should be reviewed to identify any of the following conditions:

- Significant, diffuse atherosclerosis
- A focal stenosis within 2 cm of the puncture site
- A pre-existing or procedure-related vascular complication (i.e., dissection, occlusion, AV fistula, or pseudoaneurysm)
- Vascular access obtained through a vascular graft
- Tortuous tissue puncture tract, or twisted or bent (i.e. “kinked”) procedure sheath

These conditions present an increased potential for vascular complications. In our experience, these patients should not be considered for the ANGIO-SEAL device.

Immediate re-stick – If repuncture at the same location of the previous ANGIO-SEAL device is necessary, immediately or in less than 90 days, re-entry 1 cm proximal to the previous access site can be performed safely based on published medical literature.²²

SUMMARY

Appropriate vessels and puncture locations for the ANGIO-SEAL device can be readily identified through the routine use of femoral angiography. As described here, angiographic assessment of prospective recipients for the ANGIO-SEAL device should reduce the potential for ANGIO-SEAL device deployment failure and/or complications.

ANGIO-SEAL® VIP Vascular Closure Device



PATIENT **CASE STUDIES**

The following case studies present patients who are either suitable or unsuitable for vascular closure using the ANGIO-SEAL device.

PATIENT CASE STUDIES

CASE #1:

Common Femoral Artery Puncture

Authors: Michael R. Jones, M.D. and Rick R. McClure, M.D.

Patient and angiographic data

- 38-year-old male (73 in., 215 lbs./185 cm., 98 kg.)
- Diagnostic cardiac catheterization via the right femoral artery
- 6 Fr procedure sheath
- 40° RAO, 20° caudal projection

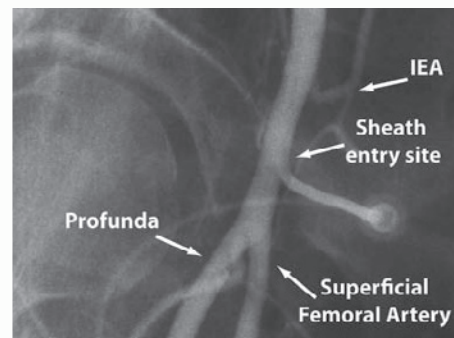
Angiographic considerations and findings

- The arterial puncture site is located within the common femoral artery
- The target vessel's lumen diameter is ≥ 5 mm
- No atherosclerosis and no side branch noted within 2 cm proximal of the puncture

Comments

The puncture site is located within a normal-sized, common femoral artery and proximal to the vessel's bifurcation. In addition, there is no evidence of any stenosis, branch vessel or other structure within 2 cm proximal to the puncture site. *Thus the patient was a good candidate for the ANGIO-SEAL device.*

Figure 1. Common Femoral Artery Puncture appropriate for the ANGIO-SEAL device.



CASE #2:

Diseased Femoral Artery, Access Site Suitable for ANGIO-SEAL Device

Authors: George Moukarbel, M.D. and Frederic S. Resnic, M.D., M.S.c.

Patient and angiographic data

- 67-year-old male (69 in., 220 lbs./175 cm., 100 kg.; BSA 2.2 m²)
- Past medical history is significant for hypertension, hyperlipidemia and peripheral artery disease. Admitted with acute coronary syndrome (ACS)
- Diagnostic left cardiac catheterization via the right femoral artery followed by coronary intervention
- Access in the right femoral artery using a 6 Fr sheath
- 27° RAO projection (Figure 1)

Angiographic considerations and findings

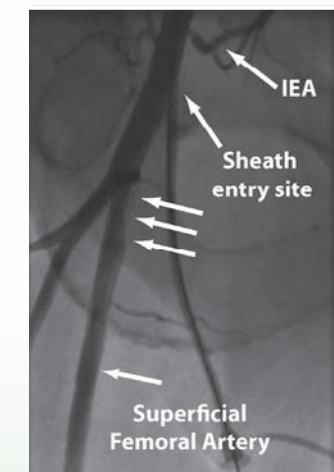
- The arterial puncture site is located in a good location in the common femoral artery (below the inferior border of the IEA and above the femoral bifurcation)
- Target vessel size is about 8 mm in diameter
- There is evidence of atherosclerotic disease in the proximal superficial femoral artery and the ostium of the IEA

Comments

Angiography at the time of catheterization showed that the location of the access sheath was favorable. Although atherosclerotic disease is evident in the superficial femoral artery, the femoral artery at the entry site of the sheath was free from disease. The artery is large. All of these characteristics make this case suitable for the ANGIO-SEAL device. The device should not be deployed at sites of atherosclerosis, as this might cause disruption of the atherosclerotic plaque and lead to dissection and other complications.

If patients have clinically significant peripheral vascular disease, based on published medical literature, ANGIO-SEAL can be deployed safely in patients with common femoral arteries > 5 mm diameter and $< 40\%$ luminal narrowing within 5 mm of the puncture site.²³

Figure 1. Femoral angiography shows the entry site of the sheath free from disease. Atherosclerosis is evident in the proximal segment of the superficial femoral artery (parallel arrows). Angiography also shows narrowing of the IEA's ostium.



PATIENT CASE STUDIES

CASE #3: Distal (Low) Arterial Puncture

Authors: Michael R. Jones, M.D. and Rick R. McClure, M.D

Patient and angiographic data

- 52-year-old female (63 in., 206 lbs./160 cm., 94 kg.)
- Diagnostic cardiac catheterization via the right femoral artery
- 6 Fr procedure sheath
- 45° RAO projection

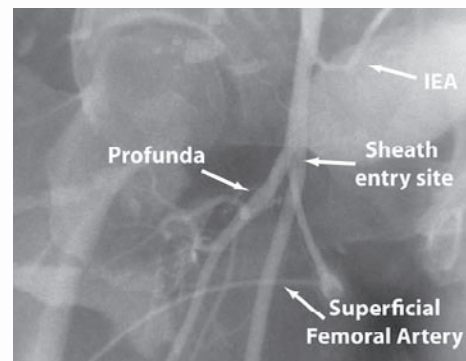
Angiographic considerations and findings

- The arterial puncture site is located within the bifurcation of the common femoral artery

Comments

As this angiogram demonstrates, the puncture site is located within the common femoral bifurcation. The ANGIO-SEAL device should not be considered for arterial punctures located within or distal to the vessel bifurcation due to an increased potential for vascular complications. *This represents an unsuitable case for the use of the ANGIO-SEAL device.*

Figure 1. Low arterial puncture not appropriate for the ANGIO-SEAL device.



CASE #4: High Femoral Puncture Site

Authors: George Moukarbel, M.D. and Frederic S. Resnic, M.D., M.S.c

Patient and angiographic data

- 82-year-old female (63 in., 165 lbs./140 cm., 63 kg.; BSA 1.68 m²)
- Diagnostic left cardiac catheterization via the right femoral artery in the setting of ACS treated with antiplatelets and anticoagulation
- 6 Fr arterial sheath
- 33° RAO projection (Figure 1, next page)
- 6 Fr ANGIO-SEAL device was deployed. Patient developed a large retroperitoneal bleed with hemodynamic instability

Angiographic considerations and findings

- The arterial puncture site is located above the inferior border of the inferior epigastric artery
- The target vessel size is 6-7 mm in diameter

Comments

Clinical and angiographic findings indicate a high risk of retroperitoneal hemorrhage in this situation. Risk factors for retroperitoneal hemorrhage have been identified in prior large studies.^{9,10,17}

These include a small body surface area (< 1.73 m²), female gender, chronic renal insufficiency and a high location of the entry site of the sheath into the femoral artery – the so-called “high stick.” (Figure 2, next page) shows the location of a desirable puncture site in the common femoral artery, which is above the femoral bifurcation and below the inferior border of the inferior epigastric artery.

The location of the puncture site in this case is high and above the level of the inferior border of the inferior epigastric artery, which identifies the site of the inguinal ligament. Studies (Farouque, et al., Ellis, et al., Tiroch, et al.) have shown increased odds of retroperitoneal hemorrhage when the entry site is above the level of the inferior border of the inferior epigastric artery. (Figure 3, next page) shows extravasation of blood into the retroperitoneal space in a patient with a “high stick.” Use of the ANGIO-SEAL device is not advisable in this situation, since the collagen plug might not be able to reach all the way across the muscle layers to the arteriotomy site when the puncture is above the inguinal ligament. This might result in a gap between the collagen plug and the arteriotomy site, leading to incomplete hemostasis and retroperitoneal hemorrhage as shown in the computerized tomography scan in (Figure 4, next page).

PATIENT CASE STUDIES

CASE #4: (continued)

High Femoral Puncture Site

Authors: George Moukarbel, M.D. and Frederic S. Resnic, M.D., M.S.c

Case 4 figures

Figure 1. Femoral angiogram in 33° RAO projection showing a high location of the entry site of the sheath above the inferior border of the femoral head.

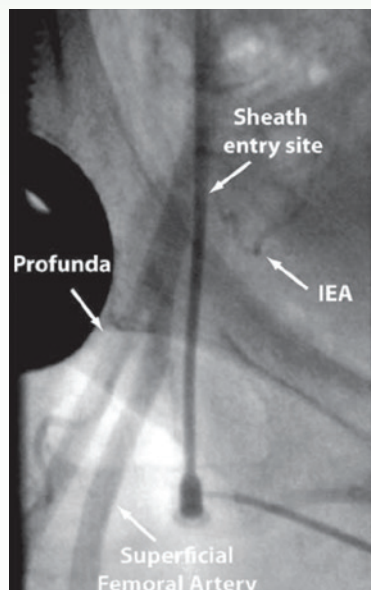


Figure 3. Femoral angiography showing extravasation of contrast material into the retroperitoneal space in a patient with "high stick."

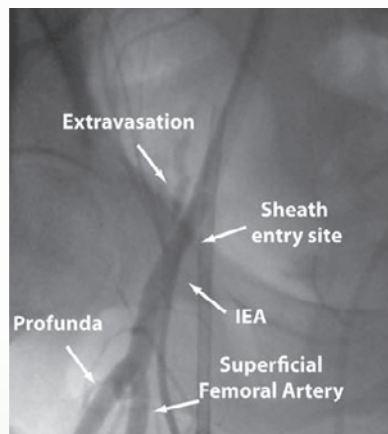


Figure 2. Femoral angiogram in 35° RAO projection showing the desired location of the entry site into the common femoral artery.

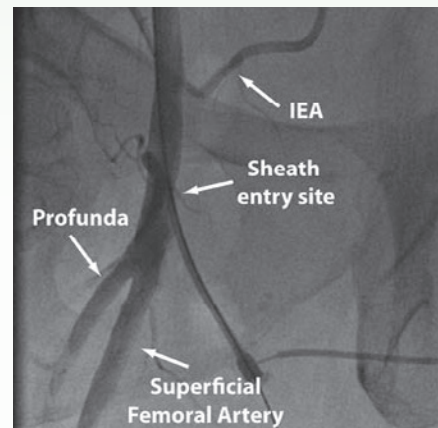
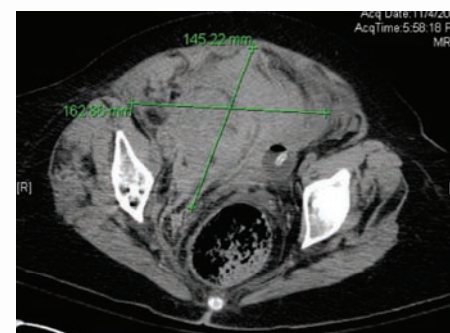


Figure 4. CT scan of the abdomen and pelvis of the patient whose femoral angiogram is shown in Figure 1, showing a large intraperitoneal and retroperitoneal hemorrhage within the pelvis, displacing the bowel and bladder toward the left side of the abdomen.



CASE #5:

High Femoral Bifurcation: Entry into the Superficial Femoral Artery

Authors: George Moukarbel, M.D. and Frederic S. Resnic, M.D., M.S.c.

Patient and angiographic data

- 79-year-old male (69 in., 190 lbs./175 cm., 86 kg.; BSA 2.0 m²)
- Diagnostic left cardiac catheterization via the right femoral artery in the setting of angina and a positive stress test
- 6 Fr arterial sheath
- 32° RAO projection (Figure 1)

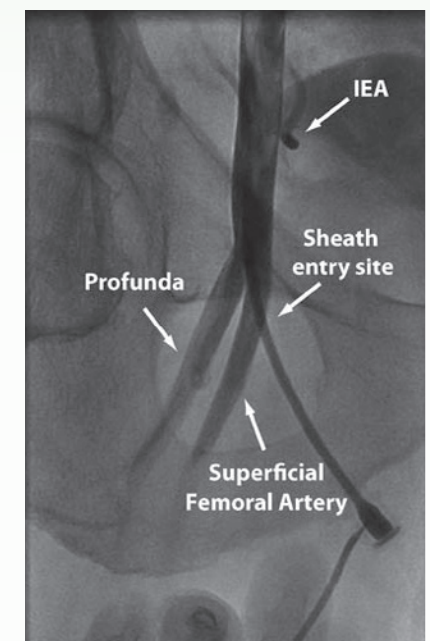
Angiographic considerations and findings

- The arterial puncture site is located below the femoral bifurcation in the superficial femoral artery
- Target vessel size is 8 mm in diameter

Comments

The femoral artery bifurcation was located at a higher-than-typical level (close to the mid femoral head). Although the location of the arterial puncture was appropriate by fluoroscopic landmarks, the sheath penetrated the superficial femoral artery. Access was managed by manual compression. However, the patient developed a pseudoaneurysm at the site of access (Figure 2, next page). This was managed by thrombin injection in the cardiac catheterization lab (Figure 3, next page). *This represents an unsuitable case for the use of the ANGIO-SEAL device.*

Figure 1. Femoral angiogram in 32° RAO projection, showing high location of the femoral artery bifurcation above the inferior border of the femoral head. The sheath is seen entering the superficial femoral artery.



PATIENT CASE STUDIES

CASE #5: (continued) High Femoral Puncture Site

Authors: George Moukarbel, M.D. and Frederic S. Resnic, M.D., M.S.c

Figure 2. Ultrasound of the right groin shows a large collection of blood with evidence of swirling blood flow inside it.

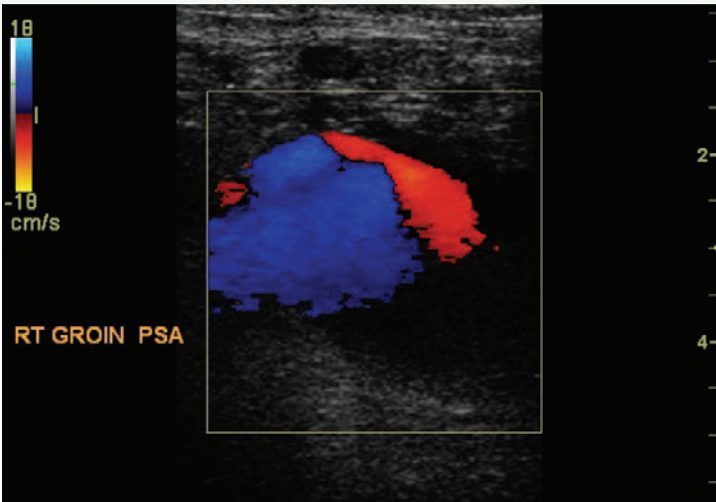
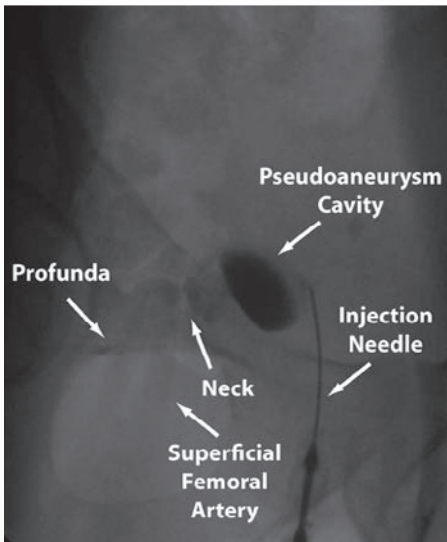


Figure 3. Femoral angiography during thrombin injection of the pseudoaneurysm. The “neck” or communication with the superficial femoral artery is also visible.



CASE #6: Femoral Artery Dissection

Authors: George Moukarbel, M.D. and Frederic S. Resnic, M.D., M.S.c.

Patient and angiographic data

- 57-year-old male (67 in., 165 lbs./170 cm., 75 kg.; BSA 1.86 m²)
- Diagnostic left cardiac catheterization via the right femoral artery for angina
- 6 Fr arterial sheath
- 37° RAO projection (Figure 1)

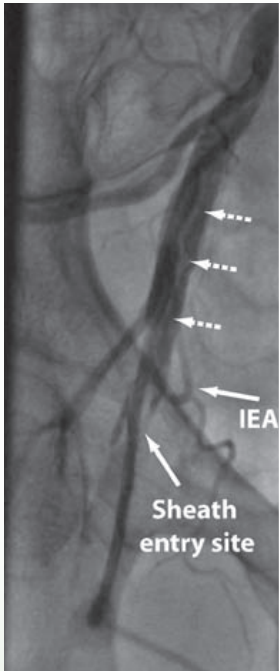
Angiographic considerations and findings

- Initial right femoral angiography through the sheath after sheath insertion revealed evidence of a dissection in the common femoral artery, likely induced by the sheath entering an atherosclerotic plaque in the vessel. There was evidence of atherosclerotic disease throughout the femoral artery. After the procedure, the patient complained of right leg pain and had diminished pulses in the foot
- The arterial puncture site is located in a desirable portion of the femoral artery, below the inferior border of the inferior epigastric artery
- Target vessel size is 7-8 mm in diameter

Figure 1. Femoral angiogram in 37° RAO projection, showing a long dissection flap (dashed arrows) extending from the femoral artery to the external iliac artery. The location of the entry site of the sheath is within the desired location. There is reduced blood flow below distal to the sheath.

Comments

Dissection of the femoral artery is a recognized complication of femoral artery access. The incidence is less than 0.3% in most published series.¹¹ This complication may arise if the access needle causes disruption of a plaque/diseased area of the vessel wall during entry. The guidewire can then track within the false lumen and propagate the dissection upward, with the access sheath then positioned in the false lumen. Sometimes, the true lumen can be re-entered from a subintimal route, as happened in this case. This complication can be avoided by making sure the guidewire is advancing freely inside the vessel. In this case, access was obtained from the contralateral side and balloon angioplasty was performed to the femoral artery to restore flow. The sheath was removed and manual compression applied. This represents an unsuitable case for the use of the ANGIO-SEAL device.



PATIENT CASE STUDIES

CASE #7: Small Vessel Diameter/Diffuse Peripheral Vascular Disease (PVD)

Authors: Michael R. Jones, M.D. and Rick R. McClure, M.D

Patient and angiographic data

- 56-year-old female (64 in., 138 lbs./163 cm., 63 kg.)
- Diagnostic left and right cardiac catheterization via the right femoral artery and vein
- 6 Fr arterial and 8 Fr venous sheaths
- 40° RAO projection

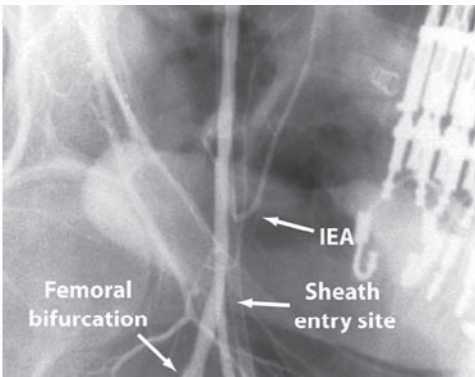
Angiographic considerations and findings

- The arterial puncture site is located within the common femoral artery
- The target vessel is ≤ 3 mm in diameter
- The angiogram demonstrates diffuse peripheral vascular disease

Comments

Arterial puncture of small vessels and clinically significant peripheral vascular disease increase the risk of a vascular complication. *This represents an unsuitable case for the use of the ANGIO-SEAL device.*

Figure 1. Small vessel diameter/diffuse PVD.



REFERENCES

1. Samal AK, White CJ. Percutaneous management of access site complications. *Catheter Cardiovasc Interv.* 2002;57(1):12-23.
2. Martin JL, Pratsos A, Magargee E, et al. A randomized trial comparing compression, Perclose ProGlide and ANGIO-SEAL VIP for arterial closure following percutaneous coronary intervention: The CAP trial. *Catheter Cardiovasc Interv.* 2008;71(1):1-5.
3. Marso SP, Amin AP, House JA, et al. Association between use of bleeding avoidance strategies and risk of periprocedural bleeding among patients undergoing percutaneous coronary intervention. *JAMA.* 2010;303(21):2156-2164.
4. Vaitkus PT. A meta-analysis of percutaneous vascular closure devices after diagnostic catheterization and percutaneous coronary intervention. *J Invasive Cardiol.* 2004;16(5):243-246.
5. Arora N, Matheny ME, Sepke C, et al. A propensity analysis of the risk of vascular complications after cardiac catheterization procedures with the use of vascular closure devices. *Am Heart J.* 2007;153(4):606-611.
6. Resnic FS, Blake GJ, Ohno-Machado L, et al. Vascular closure devices and the risk of vascular complications after percutaneous coronary intervention in patients receiving glycoprotein IIb/IIIa inhibitors. *Am J Cardiol.* 2001;88(5):493-496.
7. Rao SV, Ou F-S, Wang TY, et al. Trends in the prevalence and outcomes of radial and femoral approaches to percutaneous coronary intervention: a report from the National Cardiovascular Data Registry. *JACC Cardiovasc Interv.* 2008;1(4):379-386.
8. Kern MJ. Cardiac catheterization on the road less traveled: navigating the radial versus femoral debate. *JACC Cardiovasc Interv.* 2009;2(11):1055-1056.
9. Tiroch KA, Arora N, Matheny ME, et al. Risk predictors of retroperitoneal hemorrhage following percutaneous coronary intervention. *Am J Cardiol.* 2008;102(11):1473-1476.
10. Ellis SG, Bhatt D, Kapadia S, et al. Correlates and outcomes of retroperitoneal hemorrhage complicating percutaneous coronary intervention. *Catheter Cardiovasc Interv.* 2006;67(4):541-545.
11. Sherev DA, Shaw RE, Brent BN. Angiographic predictors of femoral access site complications: implication for planned percutaneous coronary intervention. *Catheter Cardiovasc Interv.* 2005;65(2):196-202.
12. Raphael M, Hartnell G. Femoral artery catheterization and retroperitoneal hematoma formation. *Clin Radiol.* 2001;56(11):933; author reply, *Clin Radiol.* 2001;56(11):934-935.
13. Garrett PD, Eckart RE, Bauch TD, et al. Fluoroscopic localization of the femoral head as a landmark for common femoral artery cannulation. *Catheter Cardiovasc Interv.* 2005;65(2):205-207.
14. Schnyder G, Sawhney N, Whisenant B, et al. Common femoral artery anatomy is influenced by demographics and co-morbidity: implications for cardiac and peripheral invasive studies. *Catheter Cardiovasc Interv.* 2001;53(3):289-295.
15. Seto AH, Abu-Fadel MS, Sparling JM, et al. Real-time ultrasound guidance facilitates femoral arterial access and reduces vascular complications: FAUST (Femoral Arterial Access With Ultrasound Trial). *JACC Cardiovasc Interv.* 2010;3(7):751-758.
16. Dudeck O, Teichgraber U, Podrabsky P, et al. A randomized trial assessing the value of ultrasound-guided puncture of the femoral artery for interventional investigations. *Int J Cardiovasc Imaging.* 2004;20(5):363-368.

Continued on next page

17. Farouque HM, Tremmel JA, Raissi Shabari F, et al. Risk factors for the development of retroperitoneal hematoma after percutaneous coronary intervention in the era of glycoprotein IIb / IIIa inhibitors and vascular closure devices. *J Am Coll Cardiol*. 2005;45(3):363-368.
18. Kent KC, McArdle CR, Kennedy B, et al. A prospective study of the clinical outcome of femoral pseudoaneurysms and arteriovenous fistulas induced by arterial puncture. *J Vasc Surg*. 1993;17(1):125-131.
19. Toursarkissian B, Allen BT, Petrinc D, et al. Spontaneous closure of selected iatrogenic pseudoaneurysms and arteriovenous fistulae. *J Vasc Surg*. 1997;25(5):803-808.
20. Webber GW, Jang J, Gustavson S, et al. Contemporary management of postcatheterization pseudoaneurysms. *Circulation*. 2007;11(20):2666-2674.
21. ANGIO-SEAL VIP Instructions for Use. ASIN0004. 2018-09-01.
22. Applegate RJ, Rankin KM, Little WC, et al. Restick following initial ANGIO-SEAL use. *Catheter Cardiovasc Interv*. 2003;58(2):181-184.
23. Abando A, Hood D, Weaver F, et al. The use of the ANGIO-SEAL device for femoral artery closure. *J Vasc Surg*. 2004;40:287-290.

Indications:

The Anglo-Seal Vascular Closure Device is indicated for use in closing and reducing time to hemostasis of the femoral arterial puncture site in patients who have undergone diagnostic angiography procedures or interventional procedures using an 8 French or smaller procedural sheath for the 8 F Anglo-Seal device and a 6 French or smaller procedural sheath for the 6 F Anglo-Seal device. Anglo-Seal is also indicated for use to allow patients who have undergone diagnostic angiography to safely ambulate as soon as possible after sheath removal and device placement, as well as to allow patients who have undergone an interventional procedure to safely ambulate after sheath removal and device placement.

Important Safety Information:

Possible adverse events for vascular closure devices include, but are not limited to: bleeding or hematoma, AV fistula or pseudoaneurysm, infection, allergic reaction, foreign body reaction, inflammation or edema. This device should only be used by a licensed physician (or other health care professional authorized by or under the direction of such physician) possessing adequate instruction in the use of the device, e.g., participation in an Anglo-Seal physician instruction program or equivalent.

RX ONLY. This advertisement is directed to physicians only, and not to consumers. Refer to the product labels and package insert for complete warnings, precautions, potential complications, and instructions for use.