Cath Lab Digest

A product, news & clinical update for the cardiac catheterization laboratory specialist

CATH LAB SPOTLIGHT

Ochsner LSU Health Shreveport–Heart & Vascular Institute

Paul Davison, BSN, RN, Dylan A. Clark Materials Management Coordinator, and Curtis L. Elkins, BSN, RN

Tell us about your facility and cath lab.

Ochsner/LSU Health System (OLSU) is a partnership between Ochsner Health and LSU Medical School. There are 3 campuses that comprise the Ochsner LSU Health System. Two campuses in Shreveport, Louisiana (OLSU Medical Center at Kings Highway and St. Mary's Medical Center at Margaret Street) and one hospital in Monroe, Louisiana (Conway OLSU Medical Center). OLSU is an academic and teaching facility that includes a Level 1 trauma center and multi-discipline fellowship programs that include cardiology. We are currently running 4 lab suites among the facilities with plans to expand services in the future.

continued on page xx

Happy Cardiovascular Professionals Week!
February 14-20, 2021

In This Issue

CATH LAB HEALTH

Logistical, Financial, and Psychological Impact of the COVID-19 Pandemic on Cardiac Catheterization Lab Nurses and Technologists: A U.S. National Survey

Bailey Ann Estes, BSN[1]; Joji J. Varghese, MD[1]; Jared Jacques, BS[1]; Srihari S. Naidu, MD[2]

Abstract

Objectives. Coronavirus 2019 (COVID-19) significantly impacted cardiac care delivery in a manner that has not been previously experienced in the United States. Attention and resources have focused on physicians, patients, and healthcare systems with little information regarding the effects on nurses and technologists in the cardiac catheterization laboratory (CCL). **Methods.** A national, online survey was conducted for nurses and technologists working in the CCL in the United States. The survey was self administered, anonymous, and included 45 questions assessing baseline demographics, logistical changes to workflow and responsibilities, staff preparedness, and mental health.

continued on page xxx

COMPLEX PCI

Transradial Intervention Does Not Compromise Technical Success

Katrine A. Zhiroff, MD, FACC, FSCAI

Radial artery access in coronary artery interventions has been repeatedly shown to reduce bleeding complications and improve cardiovascular outcomes. It has become the first-line approach for many operators. Despite the increased uptake of the transradial approach in the U.S. and around the world for routine diagnostic angiography and interventions on low-risk lesions, there are fewer operators using the radial artery approach as a mainstay for complex lesion subsets.

continued on page xx

Continued from cover

Transradial Intervention in Routine Complex Coronary Intervention Does Not Compromise Technical Success

Katrine A. Zhiroff, MD, FACC, FSCAI

There are perceived limitations of poor guide support, and poor tracking and deliverability. The following case demonstrates that the default transradial approach can be successfully utilized for treatment of complex lesions without compromising angiographic success. It demonstrates a planned strategy with equipment that augments guide support and allows for appropriate lesion preparation in order to ensure the deliverability of balloons and stents.

Case Report

This is a 77-year-old male with a history significant for coronary artery disease and paroxysmal atrial fibrillation on oral anticoagulation. The patient underwent percutaneous coronary intervention (PCI) of the mid left anterior descending (LAD) coronary artery several years prior in a setting of acute myocardial infarction. He presented to his primary cardiologist with complaints of new-onset dyspnea on exertion. He underwent a nuclear myocardial perfusion stress test demonstrating a reduction of ejection fraction to 44%, as well as inferior scar with peri-infarct ischemia. The patient also had a coronary computed tomography (CT) angiogram demonstrating diffuse, obstructive disease in the proximal and distal right coronary artery (RCA) with poor visualization of the mid vessel secondary to heavy calcification. He was subsequently referred for coronary angiography.

Procedure

Vascular access was obtained in the right radial artery using a back wall technique with a 21-gauge needle. Upon access of the right radial artery, a 6 French (Fr) GLIDESHEATH SLENDER® Introducer Sheath (Terumo) was advanced over a .025-inch guidewire. A radial cocktail (nitroglycerin 200 ug, verapamil 2.5 mg, heparin 5000 IU) was administered through the side port of the sheath. A standard .035-inch J tip wire was advanced, followed by a 5 Fr OPTITORQUE® Diagnostic Catheter 4.0 Tig shape (Terumo) into the ascending aorta. Diagnostic angiography of the left and right coronary systems was performed. Left main, LAD, and left circumflex arteries were patent with minimal luminal irregularities. The mid LAD stent was noted to be patent, without angiographic evidence of in-stent restenosis. No evidence of left to right collaterals was present. Selective angiography of the RCA demonstrated a mid vessel long segment subtotal occlusion and a short segment of complete occlusion with poor distal reconstitution. The lesion was noted to have moderate to heavy calcification throughout its length on angiographic review of diagnostic images.

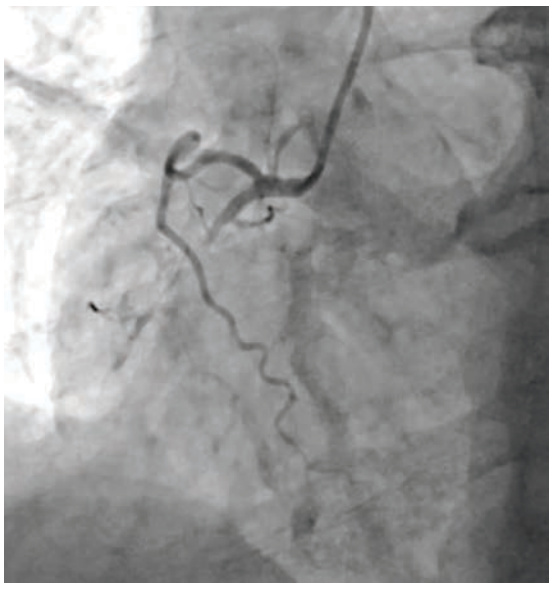

Figure 1. Selective angiography of right coronary artery (RCA), right anterior oblique (RAO) projection: mid-vessel chronic subtotal occlusion with moderate calcification and poor distal reconstitution.

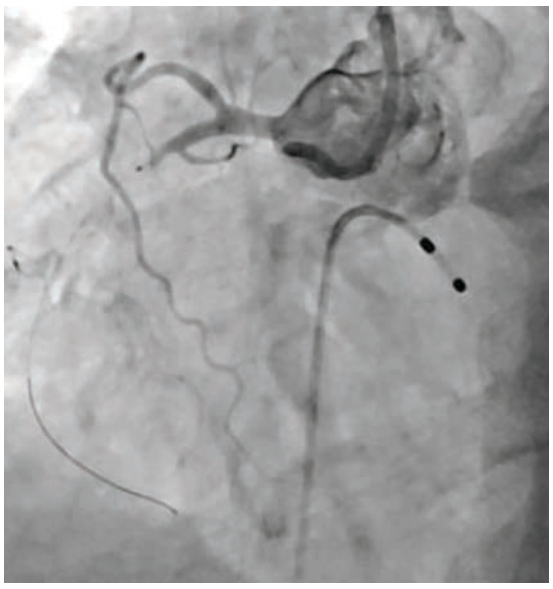

Figure 2. RCA intervention: 6 Fr Judkins left (JL) 3.5 guide. An .014-inch Fielder XT wire (Asahi Intecc) with FINECROSS MG support catheter (Terumo) successfully crossed the lesion.

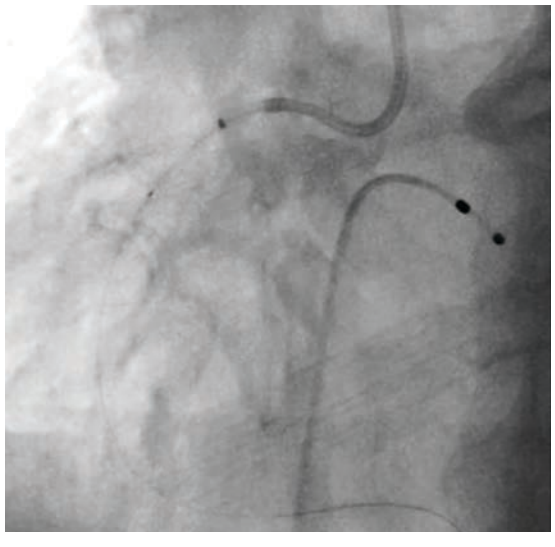

Figure 3. Successful advancement of 1.5 x 6 mm RX TAKERU PTCA balloon (Terumo) across the lesion.

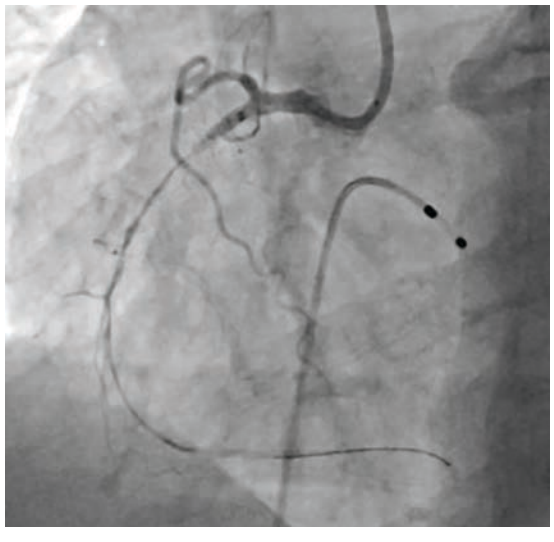

Figure 4. Successful exchange of Fielder XT wire over FINECROSS MG microcatheter for 0.009-inch RotaWire (Boston Scientific).

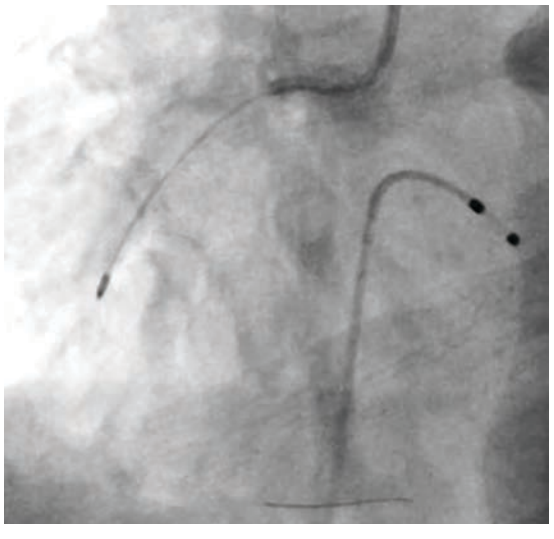

Figure 5. Performance of rotational atherectomy using 1.25 mm burr throughout the proximal, mid, and distal RCA.

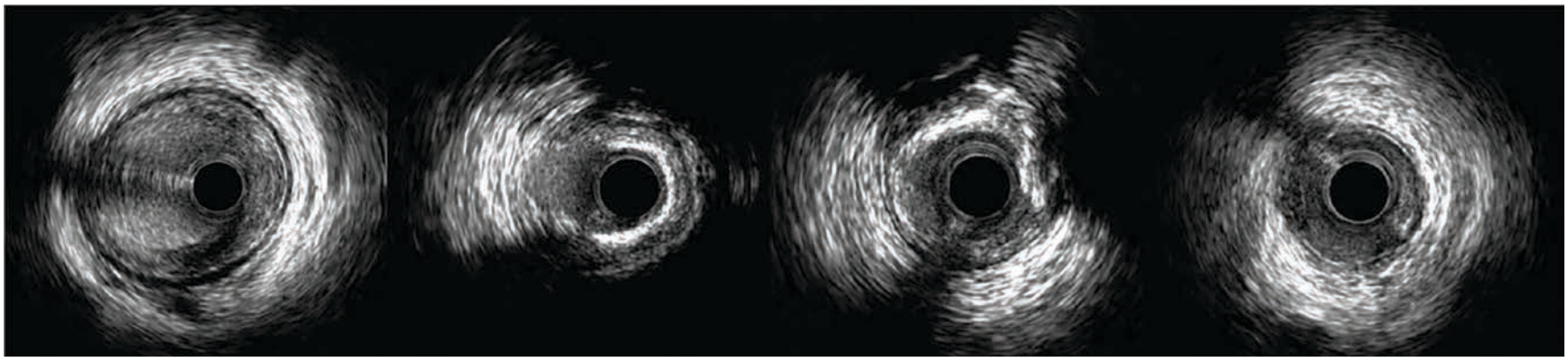

Figure 6. Intravascular ultrasound (IVUS) of RCA following rotational atherectomy. Ostial and proximal vessel reference diameter 3.75-4.0 mm, followed by heavy calcification in mid vessel occupying >270-degree arc, patent distal vessel without evidence of dissection.

Given the absence of interventional collaterals and prior CT imaging demonstrating at least a 2 mm distal RCA, an antegrade approach with rotational atherectomy was planned to address the lesion in the mid RCA. A Judkins left (JL) 0.75-inch 6 Fr guide was used to engage the origin of RCA. The lesion was approached with an .014-inch Whisper ES (Abbott Vascular) with FINECROSS® MG Coronary Micro-Guide Catheter (Terumo) support. Subsequently, the wire was exchanged for an .014-inch Fielder XT (Asahi Intecc). Once the Fielder XT wire was advanced across the lesion into the distal vessel, there was difficulty advancing the FINECROSS microcatheter. The microcatheter was then withdrawn. A GuideLiner (Teleflex) guide extension catheter was then introduced over the Fielder XT wire into the proximal RCA just proximal to the lesion. Another attempt was made to advance the microcatheter across the lesion without success. At this point, the microcatheter was exchanged for a 1.5 x 6 mm RX TAKERU™ PTCA Balloon Dilatation Catheter (Terumo). We were able to wedge the balloon in the mid lesion and begin serial dilations up to 8 atmospheres (atm), eventually being able to gently dilate the entire length of the lesion. The balloon was removed, and 1.8 Fr FINECROSS microcatheter was now successfully advanced across the lesion, allowing for exchange of the Fielder XT wire for a 0.009-inch RotaWire (Boston Scientific). The GuideLiner guide extension catheter was removed. Rotational atherectomy was performed, using a 1.25 mm burr x 3 passes at 155K rpm, followed by a polishing run. Follow-up angiography demonstrated distal vessel spasm and no reflow. A FINECROSS microcatheter was advanced over the RotaWire. The RotaWire was withdrawn and vasoactive medications (verapamil 40 mcg and adenosine 60 mcg) were administered through the catheter into the distal vascular bed. An .014-inch Whisper ES was reintroduced and the microcatheter was removed. Follow-up angiography demonstrated restoration of flow. Percutaneous transluminal coronary angioplasty was then performed with a 2.0 mm x 15 mm RX TAKERU balloon (Terumo) with recovery of TIMI-3 runoff. At this point, an Opticross HD intravascular ultrasound (IVUS) catheter (Boston Scientific) was inserted past the distal edge of the lesion to assess reference vessel diameter throughout the treated segment. Subsequently, overlapping stents were delivered and deployed in the distal, mid, and proximal RCA (2.5 x 38 mm Synergy drug-eluting stent [DES], 3.0 x 38 mm Synergy DES, and 3.5 x 12 mm Synergy DES, respectively). Final angiographic results demonstrated TIMI-3 flow, 0% residual stenosis, and no evidence of dissection, perforation, or distal embolization. After removal of the guide catheter over a wire, hemostasis was obtained at the arteriotomy site using the TR BAND® Radial Compression Device (Terumo) and patent hemostasis technique.

Discussion of Strategy and Equipment Selection

This case demonstrates that angiographic success in treating complex lesions is not compromised by a default transradial approach. In this case, it was especially critical to minimize the risk of access complications and access site bleeding because of the need for triple therapy, ie, dual antiplatelet therapy following PCI in addition to systemic anticoagulation for atrial fibrillation. Anticipation of the challenges involved in the treatment of complex, calcified lesions led to ultimate success. The presence of a complex lesion and heavy calcification on diagnostic imaging influenced the decision to use an active supportive guide catheter from the outset of the interventional procedure. The use of the FINECROSS microcatheter allowed for a seamless exchange of wires as well as the distal delivery of vasoactive medications to address no reflow. The outstanding pushability and trackability of the RX TAKERU balloon was demonstrated by its delivery into a severely calcified lesion, allowing soft pre-dilation of the lesion at low atmospheres and facilitating delivery of other equipment. Subsequent lesion preparation with rotational atherectomy allowed us to address heavy calcification of the lesion that can affect stent expansion and apposition. Guide stability allowed us to perform atherectomy in a controlled manner and to address no reflow quickly, without any effect on the patient's hemodynamic stability. We elected to use IVUS imaging to optimize selection of stent length and diameter, and eventually achieve a good angiographic result. ■

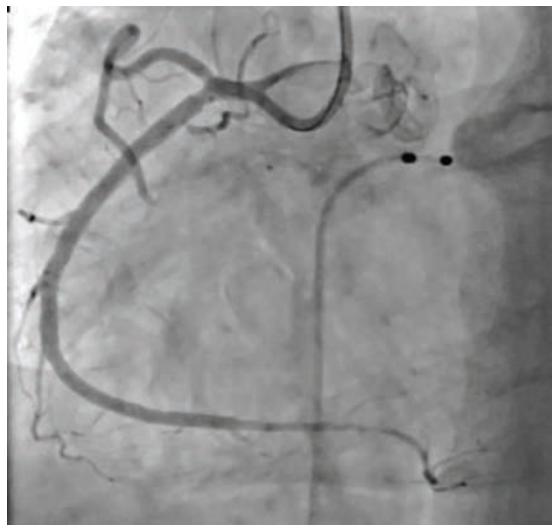

Figure 7. Final angiographic result after successful implantation of overlapping 2.5 x 38 mm Synergy (Boston Scientific) (distal), 3.0 x 38 mm Synergy (mid), and 3.5 x 12 mm Synergy (distal) stents.

This article is supported by Terumo.

Katrine A. Zhiroff, MD, FACC, FSCAI
PIH Good Samaritan Hospital, Los Angeles, California